

The pitfalls of resuscitative endovascular balloon occlusion of the aorta: Risk factors and mitigation strategies

Anders J. Davidson, MD, MAS, Rachel M. Russo, MD, MAS, Viktor A. Reva, MD, Megan L. Brenner, MD, Laura J. Moore, MD, Chad Ball, MD, Eileen Bulger, MD, Charles J. Fox, MD, Joseph J. DuBose, MD, Ernest E. Moore, MD, Todd E. Rasmussen, MD, and the BEST Study Group, Sacramento, California

ABSTRACT: Despite technological advancements, REBOA is associated with significant risks due to complications of vascular access and ischemia-reperfusion. The inherent morbidity and mortality of REBOA is often compounded by coexisting injury and hemorrhagic shock. Additionally, the potential for REBOA-related injuries is exaggerated due to the growing number of interventions being performed by providers who have limited experience in endovascular techniques, inadequate resources, minimal training in the technique, and who are performing this maneuver in emergency situations. In an effort to ultimately improve outcomes with REBOA, we sought to compile a list of complications that may be encountered during REBOA usage. To address the current knowledge gap, we assembled a list of anecdotal complications from high-volume REBOA users internationally. More importantly, through a consensus model, we identify contributory factors that may lead to complications and deliberate on how to recognize, mitigate, and manage such events. An understanding of the pitfalls of REBOA and strategies to mitigate their occurrence is of vital importance to optimize patient outcomes. (*J Trauma Acute Care Surg.* 2018;84: 192–202. Copyright © 2017 Wolters Kluwer Health, Inc. All rights reserved.)

An expert is a person who has made all the mistakes that can be made in a very narrow field. —Niels Bohr

Resuscitative endovascular balloon occlusion of the aorta (REBOA) was initially conceived as a method of hemorrhage control in 1954 by American military surgeon Carl Hughes.¹ He utilized this technique during the Korean War to treat two patients, neither of whom survived the intervention. Thereafter, the concept of using an endovascular balloon to halt ongoing distal blood loss was relegated to sporadic case reports.^{2,3} Then, in 1989, Gupta et al.⁴ published a multicenter

experience utilizing aortic balloon occlusion for penetrating abdominal trauma in 21 patients. In this series, the authors described a total of eight significant complications including paraplegia, catheter exit from vessel injury, and access site thrombosis. Because of the concern for serious complications, the technique of aortic balloon occlusion was not widely described in published literature again until the late 2000s.⁵ With advancements in endovascular technology, leaders in vascular trauma revisited this approach for the treatment of noncompressible truncal hemorrhage.⁶ In the past several years, REBOA has experienced a renaissance, with its implementation rapidly expanding worldwide.⁷

Submitted: June 11, 2017, Revised: July 20, 2017, Accepted: September 19, 2017, Published online: October 19, 2017.

From the University of California Davis (A.J.D., R.M.R., J.J.D.), Sacramento, California; Kirov Military Medical Academy (V.A.R.), Saint-Petersburg, Russian Federation; R Adams Cowley Shock Trauma Medical Center (M.L.B.), Baltimore, Maryland; University of Texas Health Science Center (L.J.M.), Houston, Texas; Foothills Medical Centre (C.B.), University of Calgary, Calgary, Alberta, Canada; Harborview Medical Center (E.B.), University of Washington, Seattle, Washington; Denver Health (E.E.M.), Denver, Colorado; Uniformed Services (T.E.R.), University of the Health Sciences, Bethesda, Maryland.

The views expressed in this material are those of the authors and do not reflect the official policy or position of the US Government, the Department of Defense, the Department of the Air Force, or any of the affiliated institutions.

The BEST Study Group (in alphabetical order): Chad Ball, MD, Foothills Medical Centre, University of Calgary, Calgary, Alberta, Canada (ball.chad@gmail.com); Megan L. Brenner, MD, R Adams Cowley Shock Trauma Medical Center, Baltimore, Maryland (mbrenner@umm.edu); Eileen Bulger, MD, Harborview Medical Center, University of Washington, Seattle, Washington (ebulger@uw.edu); Anders J. Davidson, MD, MAS, University of California Davis, Sacramento, California (ajdavidson@ucdavis.edu); Joseph J. DuBose, MD, University of California Davis (jjd3c@yahoo.com); Charles J. Fox, MD, University of Colorado Denver, Denver, Colorado (charles.fox@dhha.org); Joseph M. Galante, MD, University of California Davis (jmgalante@ucdavis.edu); Melanie Hoehn, MD, R Adams Cowley Shock Trauma Medical Center (mhoehn@smail.umaryland.edu); Tal M. Hörer, MD, PhD, Örebro University Hospital, Örebro, Sweden (Tal.horer@regionorebrolan.se); M. Austin Johnson, MD, PhD, University of California Davis (m.austin.johnson@

gmail.com); Boris Kessel, MD, Hillel Yaffe Medical Center, Hadera, Israel (bkkessel01@gmail.com); David E. Leshikar, MD, University of California Davis (deleshikar@ucdavis.edu); Junichi Matsumoto, MD, St Marianna University School of Medicine, Kawasaki, Japan (docjun0517@gmail.com); Yosuke Matsumura, MD, R Adams Cowley Shock Trauma Medical Center (yosuke.jpn4035@gmail.com); Ernest E. Moore, MD, University of Colorado Denver (ernest.moore@dhha.org); Laura J. Moore, MD, University of Texas Health Science Center, Houston, Texas (Laura.J.Moore@uth.tmc.edu); Lucas P. Neff, MD, Emory University, Atlanta, Georgia (lpneff@emory.edu); Jason Pasley, DO, R Adams Cowley Shock Trauma Medical Center (jpasley@umm.edu); Todd E. Rasmussen, MD, Uniformed Services University of the Health Sciences, Bethesda, Maryland (todd.rasmussen@usuhs.edu); Viktor A. Reva, MD, Kirov Military Medical Academy, Saint-Petersburg, Russian Federation (vrevva@mail.ru); Rachel M. Russo, MD, MAS, University of California Davis (rmrusso@ucdavis.edu); Edgardo S. Salcedo, MD, University of California Davis (esalcedo@ucdavis.edu); Thomas Scalea, MD, R Adams Cowley Shock Trauma Medical Center (tscalea@umm.edu); Nam T. Tram, MD, Harborview Medical Center, University of Washington (nam@uw.edu); Jason M. Weinberger, DO, R Adams Cowley Shock Trauma Medical Center (JasonWeinberger@umm.edu); and Timothy K. Williams, MD, Wake Forest Baptist Health, Winston-Salem, North Carolina (timothykeithwilliams@gmail.com).

Address for reprints: Lt Col Joseph J. DuBose, MD, USAF MC, Department of Vascular and Endovascular Surgery, David Grant Medical Center, 101 Bodin Cir, Travis Air Force Base, CA 94535; email: jjd3c@yahoo.com.

DOI: 10.1097/TA.0000000000001711

Despite technological advancements, REBOA is associated with significant risks due to complications of vascular access and ischemia-reperfusion. The inherent morbidity and mortality of aortic occlusion from REBOA are compounded by coexisting injury and hemorrhagic shock. In addition, the potential for REBOA-related injuries is exaggerated because of the growing number of interventions being performed by providers who have limited experience in endovascular techniques, inadequate resources, and minimal training in the technique and who are performing this maneuver in emergency situations.⁸ In an effort to ultimately improve outcomes with REBOA, we sought to compile a list of complications that may be encountered during its use. Unfortunately, the literature on REBOA complications is limited to small retrospective case series, propensity analyses, and animal studies. To address this current knowledge gap, we sought to assemble a list of anecdotal complications from high-volume REBOA users internationally. More importantly, we sought to identify contributory factors through a consensus model that may lead to complications and deliberate on how to recognize, mitigate, and manage such events.

METHODS

Drawing from personal experiences from experts in the field and published literature where available, we sought to catalogue complications of modern REBOA use around the world.

To date, there is a paucity of published information on strategies for the prevention, rapid identification, and management of REBOA complications. To address this knowledge gap, we solicited anecdotal descriptions of complications and challenges from practitioners frequently using REBOA in North America, Europe, and Asia.^{9–11} Through personal correspondence, we queried high-volume users on complications they have observed as well as their strategies for complication prevention, recognition, and management. The primary author collated these anonymously into manuscript format and added supplementary references from published literature where available. The manuscript version was then sent to all members of the study group for comment and critical review. Changes were then anonymously incorporated, and the final manuscript was sent to the authors for final approval. The process was similar to a nominal consensus model once the study group was presented with a collated manuscript, yet it preserved the anonymity of a Delphi model for the initial round of complication solicitations.¹²

The technique of REBOA has been broken down into six specific steps. These steps are similar to the original technique described by Stannard et al.¹³ and are the steps taught in several endovascular trauma management courses.^{14,15} The steps include arterial access, balloon positioning, balloon inflation, management during balloon occlusion, balloon deflation, and sheath removal/postresuscitation care. Each of these steps introduces the potential for complications, many of which can be mitigated

TABLE 1. Potential Complications and Challenges Associated With Each Step of REBOA

Step	Potential Complication	Challenges
Arterial access	Inability to obtain access Bleeding Improper location of arterial puncture Venous access	Body habitus Hypotension Hypoxia Vasospasm Variant anatomy Calcified lesions Inexperience Junctional injury
Balloon positioning	Wrong anatomical location Inability to pass catheter	Arterial injury Misalignment of arterial access Preexisting vascular pathology
Balloon inflation	Arterial injury/rupture Balloon rupture Unintended ischemia	Requires tactile feedback Balloon burst pressure Balloon misalignment
Management during balloon occlusion	Exacerbation of proximal injuries Balloon migration/prolapse Increasing ischemic burden Supraphysiologic proximal pressures Thrombosis of access site	Undiagnosed proximal injury Duration of occlusion Active resuscitation Increasing proximal pressure Arterial occlusion due to sheath Distal ischemia
Balloon deflation	Cardiovascular collapse/hypotension Clot disruption with ongoing hemorrhage Hyperkalemia Acidosis	Ischemia-reperfusion injury Coordination of resuscitation Rapid/unpredictable return of distal flow
Sheath removal and postoperative management	Hematoma or pseudoaneurysm Thromboembolism Arterial dissection Limb loss/amputation	Access site vascular injury Vasospasm Additional procedure(s) required

with careful adherence to principles of endovascular techniques and an understanding of the physiologic response to aortic occlusion. Each section reviews the challenges related to each procedural step, as well provide potential strategies for preventing, avoiding, and identifying adverse events and complications due to REBOA (Table 1).

DISCUSSION

Step 1: Arterial Access

Establishing arterial access is the first step in performing REBOA and is often the most technically challenging. Whereas arterial access is common to multiple types of procedures, the trauma population often presents unique challenges not encountered in other populations. A chaotic clinical environment, a pulseless patient undergoing cardiopulmonary resuscitation, and the need for rapid intervention all may increase the technical difficulty of vascular access.¹⁶ Hemorrhagic shock, vasospasm, and catecholamine surge can narrow blood vessels, making them more difficult to locate and cannulate. Because of this inherent difficulty, arterial access is the most time-consuming step for REBOA and may represent a bottleneck to obtaining endovascular hemorrhage control.¹⁷ In addition, hypothermia, acidosis, coagulopathy, platelet dysfunction, and hyperfibrinolysis may increase the risk of bleeding from the access site. Alternatively, other conditions may favor a thrombotic complication. In fact, a majority of severely injured patients are hypercoagulable at hospital presentation.¹⁸ Many of these factors are unavoidable; thus, emergent arterial cannulation for REBOA is inherently higher risk than similar procedures performed in the elective setting.

Ideally, arterial access for REBOA is obtained in the common femoral artery (CFA) overlying the femoral head below the inguinal ligament. This location allows cannulation in a larger-diameter artery, which carries less risk of arterial thrombosis than cannulation of the superficial femoral artery (SFA). In comparison, accidental proximal puncture of the external iliac artery can lead to uncontrolled, noncompressible retroperitoneal hemorrhage during and/or after intervention. Even under ideal circumstances, identification of the CFA can be difficult because its length is short (approximately 4 cm in most patients).¹⁹ Notably, the portion of the artery most accessible to manual palpation is often located over the SFA. One strategy to improve successful arterial cannulation in the emergent setting includes ultrasound guidance to enhance identification of the CFA.²⁰ An alternative method is to expose the artery by open cut-down. The bifurcation of the SFA and profunda femoris artery is often a helpful landmark used to confirm the location of the CFA. Regardless of approach, a review of vascular anatomy and corresponding external landmarks is useful for REBOA providers.

The CFA is a fingerbreadth below the inguinal ligament and may require retraction of a pannus or a longer access needle in obese or pregnant patients. It is worth emphasizing that inguinal skin folds are a poor landmark for localization of the CFA. Alternatively, the anterior superior iliac spine and the pubic tubercle provide consistent prediction of the proximal boundary of the CFA. It is also worth noting that variant anatomy, arterial tortuosity, or atherosclerotic lesions may increase difficulty with arterial access. Many of the authors in the BEST

study group have experienced difficulty obtaining emergent arterial access, particularly in their early experience. Alarmingly, we have also observed inadvertent inferior vena cava cannulation by inexperienced providers because of difficulty differentiating between arterial and venous blood in hypoxic and hypotensive patients. Thus, some authors favor open arterial cut-down as opposed to percutaneous cannulation for patients in extremis. Bleeding from the access site can be controlled with local pressure, through suturing, or with a hemostatic dressing around the sheath.

Some experts recommend first accessing the artery with a 4 Fr to 5 Fr micropuncture catheter. Advocates of this approach suggest that the smaller sheath can be used proactively in patients who may deteriorate, allowing for arterial blood pressure monitoring and collection of blood samples.²¹ The micropuncture catheter can then be rapidly exchanged for a 7 Fr to 8 Fr sheath via the Seldinger technique for REBOA access with a relatively low risk of serious complications.^{22,23} Some authors recommend initial cannulation with a 7 Fr to 8 Fr sheath in order to avoid time-consuming catheter exchanges, as initial 7 Fr access adds minimal risk over micropuncture catheters.

Obtaining arterial access prior to intubation or induction of anesthesia may be warranted in order to have arterial monitoring and potential REBOA access prior to potential hemodynamic collapse that can occur after the administration of paralytics or anesthetic agents.^{24,25} Similarly, arterial access may be desired prior to transporting transient responders to the computed tomography scanner or intensive care unit in the event REBOA becomes necessary. A few of the authors have utilized REBOA as

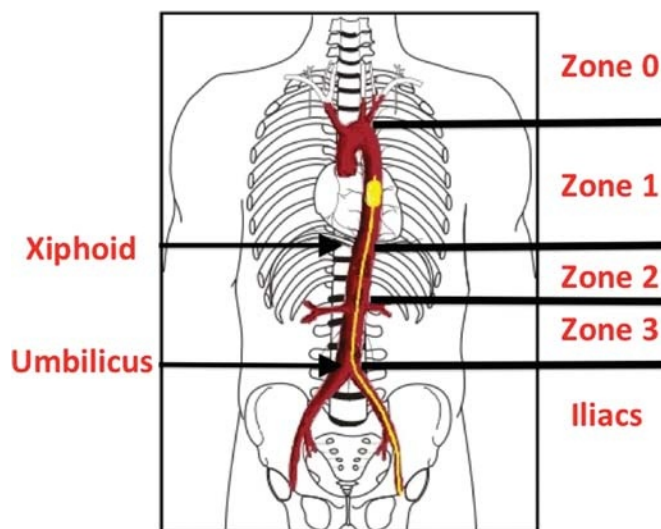


Figure 1. Zones of the aorta and anatomical landmarks for REBOA placement. Zone 0 is proximal to the origin of the left subclavian artery. Zone 1 is distal to the origin of the left subclavian and proximal to the celiac axis. Zone 2 is distal to the celiac axis and proximal to the origin of the renal arteries. Zone 3 is distal to both renal arteries and proximal to the bifurcation into the iliac arteries. The external landmark for Zone 1 is for the entire balloon to be above the xiphoid process. The external landmark for Zone 3 is for the entire balloon to be above the umbilicus.

a resuscitative adjunct prior to computed tomography scan, but this practice remains controversial.²⁶ This arterial access may be utilized for other endovascular procedures even if REBOA is not required. Similarly, when REBOA is considered, bilateral arterial access may be useful. A second access site can be used for reliable distal arterial pressure monitoring and access for additional endovascular procedures under REBOA inflation.

There is no consensus as to when arterial access should be performed. However, it should be noted that once arterial access is obtained, time to aortic occlusion is significantly shorter with REBOA as compared with traditional thoracotomy.¹⁷ The risks of arterial access need to be balanced with the concept that access may become more difficult the longer one waits. Therefore, many in the study group recommend routine small sheath placement in patients with sustained systolic blood pressure of less than 90 mm Hg. As there may be significant risks conferred with either premature or delayed sheath placement, REBOA providers should carefully consider the appropriate timing for arterial access in each case.

Step 2: Balloon Positioning

Selecting the most appropriate anatomic location for balloon inflation is critical and is based on aortic zones.¹³ The two anatomical locations described for REBOA are Zone 1 (distal to left subclavian origin; proximal to celiac axis) and Zone 3 (distal to renal arteries; proximal to aortic bifurcation) (Fig. 1). Inflating an occlusion balloon in the wrong arterial location can be catastrophic. Zone 1 occlusion has a greater risk of organ

ischemia, with few patients surviving complete occlusion times longer than an hour.^{27,28} On the other hand, Zone 3 occlusion may have a longer tolerable occlusion time, but does not control any hemorrhage above this level, and provides less support to myocardial and cerebral perfusion.²⁹ Malposition of the balloon can be even more catastrophic. Inflation of the balloon catheter within the aortic arch or heart (Zone 0) has the potential to induce myocardial damage directly, by creating excessive ventricular afterload, or by direct occlusion of the vessels providing cerebral blood flow.³⁰ Inflation in the visceral segment of the aorta (Zone 2) can increase blood flow through the celiac axis, worsening upper abdominal hemorrhage while inducing renal ischemia. Inadvertent balloon inflation in the iliac artery may exacerbate proximal hemorrhage and increases the potential for arterial damage. Most of the authors have experienced one or more of the above complications due to misalignment of the REBOA catheter (Fig. 2).

Once the desired location for balloon occlusion has been selected, various methods of positioning the catheter have been described. Early use of REBOA confirmed catheter position with fluoroscopy prior to balloon inflation, and many practitioners still commonly use this strategy with a mobile C-arm.³¹ Notably, the potential for guidewire or catheter malposition, migration, or displacement remains a recognized risk of all endovascular procedure. When using a stiff guidewire, providers must be vigilant of the position of both wire and balloon catheter. The authors have experienced a number of complications when careful attention was not paid to positioning of the

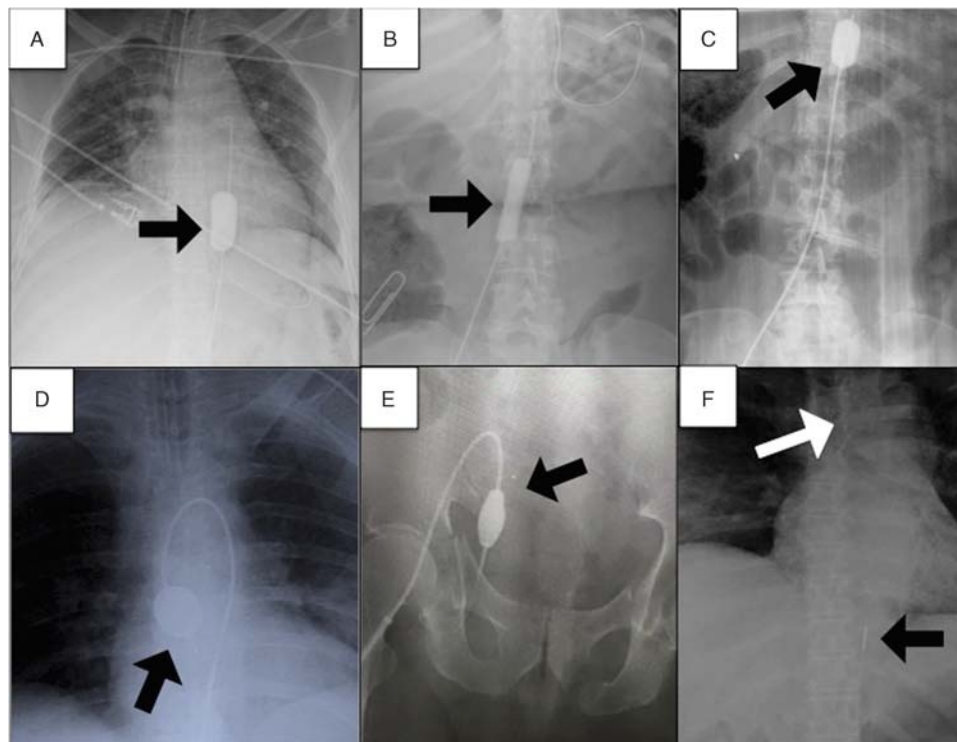


Figure 2. Malposition of REBOA balloons. (A) Appropriate position within Zone 1 of the aorta. (B) Appropriate position within Zone 3 of the aorta. (C) Inadvertent position within Zone 2 of the aorta. (D) Inadvertent position within Zone 0 of the aorta. (E) Inadvertent position within the ipsilateral internal iliac artery. (F) Exacerbation of proximal aortic hemorrhage (white arrow, note widened mediastinum) following inflation of a distally located balloon (now deflated). Black arrows denote balloons.

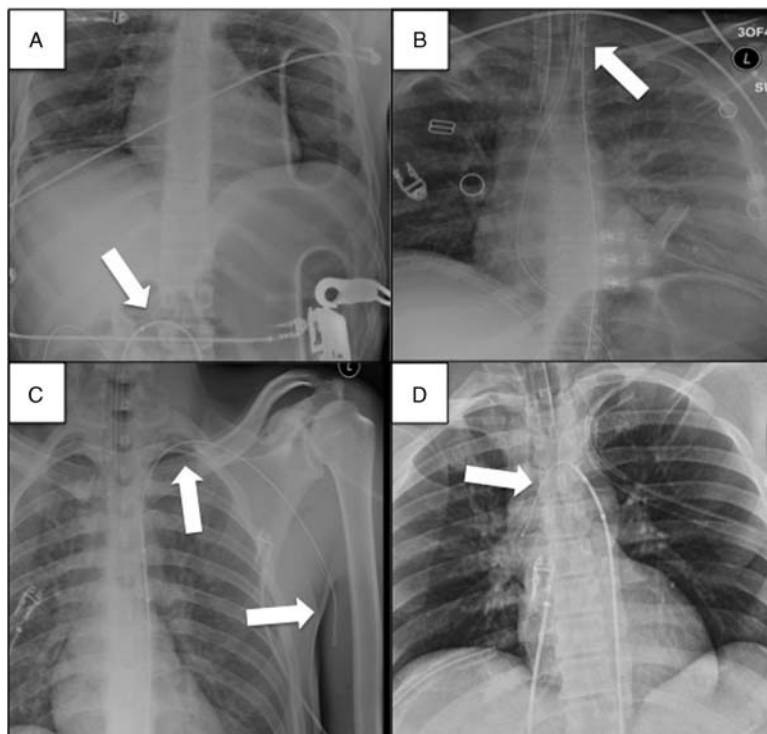


Figure 3. X-ray depictions of wire malposition. (A) Exit of the wire through an injury in the aorta. (B) Inadvertent advancement of the wire into the left carotid artery. (C) Inadvertent advancement of the wire into the left subclavian, axillary, and brachial artery. (D) Inadvertent advancement of the wire into the aortic arch. White arrows denote wire.

guidewire (Fig. 3). Alternatively, fluoroscopy-free catheters have been developed specifically for REBOA when advanced imaging is unavailable. These catheters do not require a guidewire, have a J-curved and flexible tip, and are made of stiffer Nitinol (nickel titanium)-based material to resist diversion into side branches of the aorta.³² Centimeter markings on the catheter allow for the use of external measurements based on anatomic landmarks in order to estimate the distance into the desired aortic zone. Although these anatomic landmarks have been validated in cadaver models,^{33,34} there remains a risk of improper measurement. For proper placement into the Zone 1 aorta, the bottom of the balloon should be placed at the xiphoid process.¹³ Because the balloon is not at the tip of the catheter, some providers use the position of the tip of the catheter at the sternal notch to approximate Zone 1. While the two methods of measurement both result in proper positioning of the occlusion balloon when performed correctly with the ER-REBOA catheter (Prytime Medical, Boerne, TX), these methods may not be interchangeable with all REBOA catheters. Similarly, if the provider were to confuse the two methods and measure the tip of the catheter at the xiphoid, the error would result in distal malposition of the catheter. If a similar mistake were made when using the umbilicus to estimate Zone 3 occlusion, the balloon might be inadvertently inflated in an iliac artery. Regardless of measurement method, providers should be aware that the entire balloon needs to be above the target of interest to provide optimal hemorrhage control. Therefore, measurements should be from the bottom of the balloon for most REBOA catheters. In addition, external anatomic measurements might not be accurate in morbidly obese or pregnant patients. For these reasons, many

providers advocate ultrasound guidance or x-ray confirmation prior to balloon inflation.^{32,35-37}

Once proper positioning is achieved, the catheter must be secured in position to avoid migration during inflation and occlusion. When using techniques such as intermittent and partial REBOA, care must be taken to note the catheter position, as lack of apposition to the aortic wall during balloon deflation increases the risk of downstream migration.^{23,25,38-40} If an over-the-wire technique is used, the guidewire should be left in place to provide support to the catheter; and the soft tip of the wire should extend beyond the catheter. Many of the authors have experienced balloon prolapse when using these catheters after wire removal, or if the flexible portion of the wire is not advanced far enough proximal to the catheter.

Additional anatomical as well as technical challenges exist. During balloon placement, there may be difficulty advancing the catheter. This may be due to arterial thrombosis or disruption, placement into an aortic branch vessel, or placement through an area of vessel injury (Fig. 3). In addition, preexisting vascular pathology may make catheter advancement difficult. This includes the presence of an arterial dissection flap, as well as variant anatomy caused by tortuosity, atherosclerosis, or an aneurysm. Because of the risk of iatrogenic injury, the catheter should not be forcefully advanced if resistance is met. If resistance is met, an imaging study should be performed to determine the location of the balloon. Collectively, the authors have experienced numerous instances of wire or catheter malposition; including the contralateral iliac artery, internal iliac artery, deep iliac circumflex artery, and even the inferior epigastric artery. The challenges to guidewire or catheter advancement into a

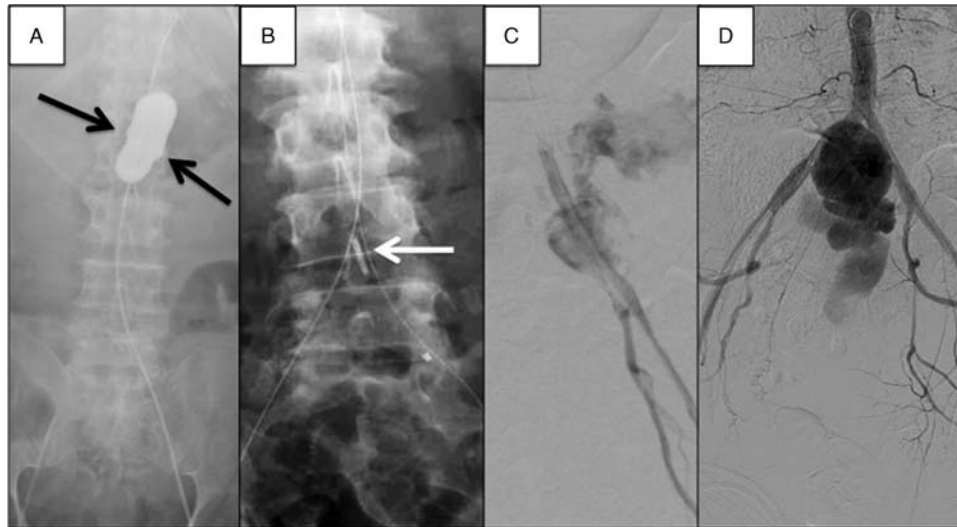


Figure 4. Complications of balloon inflation. (A) Overinflation of REBOA balloon just prior to arterial rupture. Note the balloon extending into the renal arteries due to overpressure (black arrows). (B) Balloon prolapse into the iliac artery leading to iliac artery rupture upon inflation. (C and D) Iliac artery rupture due to malposition and overinflation of the balloon.

desired location may require an alternative anatomical site for access (i.e., brachial or contralateral leg) or an alternate plan/adjunct for hemorrhage control. If time allows, image-guided placement of an endovascular wire may overcome anatomical challenges; however, in the unstable patient with arterial injury or unsuitable anatomy, conventional endovascular techniques may not be applicable.

Step 3: Balloon Inflation

Once the balloon is confirmed to be in the proper location, it must be manually inflated until aortic flow is halted. Most authors recommend a period of complete occlusion to promote clot formation; however, some authors simply recommend balloon inflation until desired proximal pressure is achieved.

Balloon inflation is usually performed blind during REBOA. Balloon inflation should cease when distal pulses (if previously present) disappear or when resistance to inflation develops. Providers new to endovascular balloon inflation may not have developed the tactile sensitivity to recognize subtle changes in resistance to inflation and may mistakenly select a goal balloon volume instead. Overinflation of the balloon may lead to artery or balloon rupture (Fig. 4).^{4,5,41,42} In addition, overinflation can lead to aortic overpressure injury, creating an arterial dissection or intimal injury that can lead to long-term vascular complications. In addition, the presence of aortic plaques, vascular injury, and the excitement inherent during emergent procedures performed to rescue a patient in extremis all contribute to these risks.

In the absence of imaging, a distal arterial waveform may be measured from the insertion sheath.⁴⁰ If present prior to balloon inflation, the waveform will disappear upon complete aortic occlusion. However, severe vasospasm or limited flow between the sheath and catheter may preclude the measurement of a distal arterial waveform.²³ Therefore, some providers recommend using either a slightly larger sheath or an additional contralateral sheath to improve distal hemodynamic monitoring. Similarly, Doppler ultrasound of the contralateral femoral artery may be used to confirm aortic occlusion. In the absence of these

adjunctive measures, the return of radial pulses and the loss of previously present femoral pulses bilaterally can also be used to confirm adequate inflation. If there is no change or weakening of distal pulses, this suggests malposition of the catheter. Similarly, the loss of a single femoral pulse indicates iliac placement. If these occur, inflation should be halted, and the catheter should be repositioned. If fluoroscopy or x-ray is available, we recommend inflating the balloon with a mix of saline and contrast. This will aid with identification of the balloon on subsequent imaging. Under fluoroscopy, once the balloon reaches the aortic wall, the balloon will begin to conform to this shape, indicating occlusion has occurred. Alternatively, sequential plain x-rays can be used.

Redistribution of circulating blood volume during balloon occlusion may exacerbate injuries proximal to the balloon because of dramatic increases in blood pressure and flow, destabilizing clot and resulting in increasing hemorrhage.^{43,44} It is the opinion of most of the authors that any signs of proximal great vessel injury preclude the use of REBOA.³⁹ In addition, it is the opinion of several of the authors that any thoracic or brain injury precludes the inflation of a REBOA balloon because of the risk of worsening proximal injuries.⁴⁵

Lastly, it is important to emphasize that the balloon needs to be deflated prior to repositioning the catheter. One of the authors observed the balloon becoming entrapped in the renal arteries as the catheter was forced above the balloon: preventing balloon deflation. This ultimately resulted in renal failure due to the prolonged period until the balloon could be deflated.

Step 4: Management During Balloon Occlusion

Optimal management of REBOA during balloon occlusion is a source of controversy and was highly debated during the inaugural endovascular trauma management meeting held in Örebro, Sweden, in February 2017.^{5,46-48} Much of what we understand about the physiologic effects of balloon occlusion for trauma remains unclear. It is known that balloon inflation results in alterations of blood volume that can have extreme physiologic consequences.⁴⁹ Efforts are underway to understand

optimal resuscitation paradigms, the maximum duration of occlusion, and alternative techniques to extend or expand the use of REBOA.

The maximum ischemic threshold is not easily extrapolated from the current literature, as most patients already have some ischemic burden present due to hemorrhagic shock. One area of consensus is that the ischemic burden due to REBOA increases as occlusion time increases. The cessation of distal blood flow results in distal organ ischemia, vasodilation, and a buildup of toxic metabolites.^{46,50,51} Therefore, once the balloon is inflated, a plan should be quickly developed and enacted in order to achieve hemorrhage control. The authors have seen multiple instances of delays in treatment that have occurred while the balloon was inflated. Many of the adverse outcomes observed from REBOA have occurred because of these interruptions before definitive care. It cannot be overstated that providers need to maintain a sense of urgency to achieve a physiologic state where the balloon may be deflated.

Mechanisms to reduce occlusion time and restore distal perfusion include intermittent REBOA, partial REBOA, and repositioning the catheter to more distal levels of occlusion as able.^{21,40,47,49,52} Alternative resuscitation strategies including selective delivery of products to the proximal or distal circulation, novel automated aortic control devices, and REBOA combined with arterial bypass are being developed to further extend the tolerable duration of ischemia but have not yet been widely used clinically.^{53,54} Spinal cord ischemia with thoracic aortic occlusion remains a major concern, as it is a described consequence of thoracic aortic occlusion.⁴ Early reports of REBOA survivors have not indicated a high rate of procedure-related paralysis. The effect of REBOA on spinal cord perfusion remains an area of ongoing research.

Brisk resuscitation infusion rates during balloon occlusion may create supraphysiologic blood pressure and flow to proximal organs.^{55,56} This may lead to a significant increase in proximal aortic blood pressure beyond what is desired, risking myocardial dysfunction, pulmonary inflammation, cerebral edema, or exacerbating intracerebral hemorrhage.^{57,58} Supraphysiologic pressures created by REBOA has been implicated in development of cardiopulmonary complications including acute respiratory distress syndrome and heart failure.⁵⁹ Furthermore, supraphysiologic blood pressures may also worsen proximal injuries that were not apparent during hypotension. Thus, there is increasing evidence that resuscitation infusion rates should be carefully titrated while the balloon is inflated. Patient management while REBOA is in place is truly a team sport, and communication is paramount among all team members.

Step 5: Balloon Deflation

Balloon deflation is the final step in the actual performance of REBOA and is potentially the most hazardous. Multiple approaches have been described, yet there is no consensus as to the best method for deflating the balloon once aortic occlusion is no longer required.^{5,14,15} Slow, methodical balloon deflation is generally advised, as abrupt loss of aortic afterload results in reallocation of circulating blood volume to a much larger volume of distribution. The combined effect is profound vasodilation and a bolus of ischemic metabolites returning to systemic circulation that may lead to cardiovascular collapse.^{29,55} Early reports

of REBOA described refractory hypotension that led to death despite reinflation of the occlusion balloon.^{5,60} Current guidelines advocated in the Basic Endovascular Skills for Trauma course recommend slow, graded balloon deflation over a period of approximately 5 minutes.¹⁴ However, recent animal models demonstrated that this technique does little to mitigate the sudden return of aortic blood flow and concomitant drop in mean arterial pressure that ensues when deflating current compliant aortic balloons.⁶¹

Much like managing return of systemic circulation following removal of an aortic clamp, REBOA deflation requires a team approach to resuscitation. Communication between the surgeon and anesthesiologist is essential to time the delivery of blood products and adjunctive medications as the balloon is deflated. Some authors use vasoactive medications as a bridge for blood pressure support following balloon deflation and utilize end-tidal CO₂ to guide reperfusion. Calcium administration may mitigate the cardiac effects of hyperkalemia and counteract citrate from blood product administration. Animal studies have shown that aggressive treatment of hyperkalemia with calcium, insulin, and dextrose was required after prolonged balloon occlusion.⁵⁹ Arterial blood gasses should be obtained frequently and at regular intervals to detect any abnormalities during reperfusion and to guide subsequent treatment. Hemostasis should be confirmed once blood pressure has improved to ensure no additional bleeding ensues when blood flow has returned to the area of injury. Lastly, it is worth noting that reperfusion following REBOA deflation may exacerbate trauma-induced coagulopathy.⁶²

The authors recommend that the balloon should be deflated as slowly as possible. If distal arterial monitoring is available, an increase in distal pressure and the emergence of a pulsatile waveform are the first indicators that aortic flow is beginning to return.^{55,61} The balloon may be deflated rapidly until the distal waveform returns, at which point the rate should significantly decrease. If arterial blood pressure drops significantly, volume should be added to the balloon. If the patient becomes unstable, reinflation of the balloon may be required.

Step 6: Sheath Removal and Postresuscitation Care

Optimal management of the sheath while in the CFA of trauma patients is another area of debate. Typically, once REBOA is no longer required, the catheter should be removed as soon as hemostasis has been achieved and coagulopathy resolved. The arterial sheath can be maintained for a period for blood pressure monitoring and for rapid access in the event REBOA is again needed. However, most of the authors advocate for sheath removal as soon as possible.

Early experience in Japan and Russia reported multiple cases of lower-extremity amputation following REBOA access in the ipsilateral limb after using 10 Fr to 14 Fr arterial sheaths.^{27,63} There is similar anecdotal evidence in the United States (Fig. 5). Experts suggest that this finding may be the result of large sheath size, small vessel diameter, and long duration of arterial cannulation. In early reports from Japan, the intra-aortic occlusion balloons used (MERA, Tokyo, Japan) required 10 Fr sheaths. Now currently, most centers have moved to lower-profile catheters (ER-REBOA [Prytime Medical]; Rescue Balloon [Tokai Medical Products, Aichi, Japan]) that may be placed through 7 Fr sheaths. These smaller sheaths have been shown to have

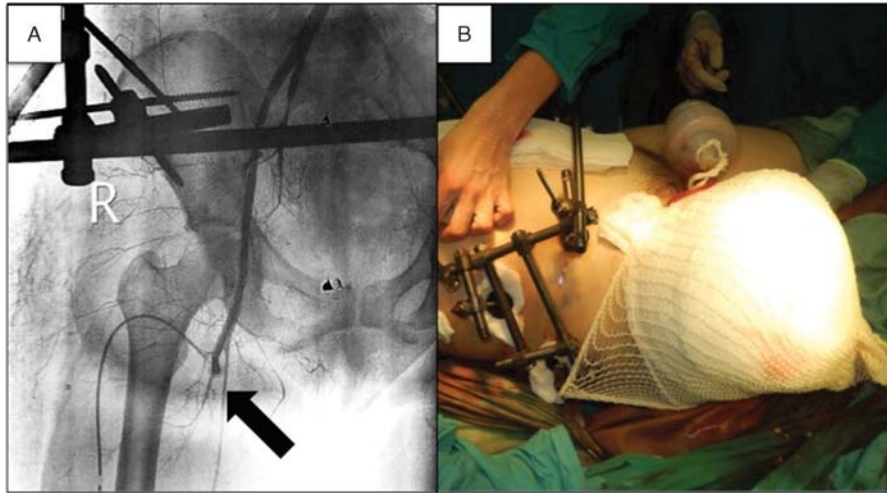


Figure 5. Limb ischemia following REBOA. (A) Complete thrombosis of CFA (B) requiring above-the-knee amputation.

fewer complications, even when in place for more than 24 hours.^{22,64} Nonetheless, reports of arterial thrombus formation have been reported following only minutes of the low-profile REBOA, and there is scattered anecdotal evidence of lower-extremity amputations that have occurred despite use of small sheaths.³⁹ This has led some authors to recommend routine angiography prior to sheath removal.²³ Most authors agree that duplex ultrasonography of the ipsilateral leg should be done routinely as a minimum standard.

Routine extremity care and monitoring have not been established. Continuous arterial Doppler and frequent compartment pressure monitoring have been suggested as adjuncts after REBOA, particularly in patients with concomitant extremity injury. However, the presence of audible Doppler signals distally does not preclude partial thrombosis or compartment syndrome. The authors have experienced cases of partial thrombosis of the femoral artery despite the presence of audible distal Doppler signals. Most authors agree that continuous low-volume crystalloid administration through the sheath is a low-risk method to reduce the risk of arterial thrombosis. Whereas systemic heparin is often contraindicated in trauma patients, intermittent heparin flushing or continuous low-dose heparin infusion via indwelling

arterial sheaths has been utilized to decrease sheath-related thrombosis in other populations.^{65,66} However, this routine practice remains controversial in the trauma patient.

Vessel diameter increases with height and age; thus, patients of small stature, particularly women and children, may be at higher risk of ischemic complications from arterial cannulation. Furthermore, younger patients have more dynamic vasculature in response to trauma. Although these concerns exist, a single series of REBOA in patients younger than 18 years has been published in Japan with no reported instances of lower-extremity amputation.⁶⁷ The study reports that, although there are no data available on the size sheath or catheter used, a trend toward lower-profile REBOA catheters with 7 Fr sheaths has evolved in Japan during that time. Smaller vessel diameter can also create the need for additional complex vascular reconstructions. Thus, care must be taken during sheath insertion to avoid complications following removal. If an arterial defect is large, or thrombosis is present, the patient will likely require another procedure (Fig. 6). One series of access site complications described a multitude of reconstructive procedures including thrombectomy, dissection flap repair, patch angioplasty, interposition grafting or bypass, and lower-extremity fasciotomy.²² If

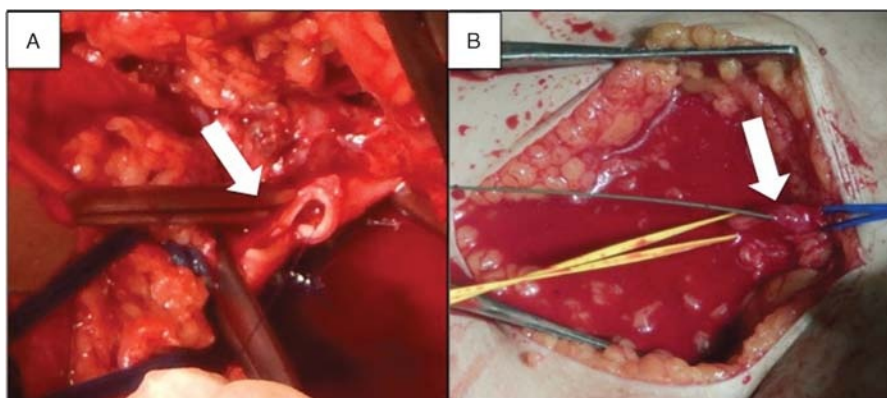


Figure 6. Access site complications. (A) Represents near transection of the CFA following REBOA sheath removal, requiring open repair. The white arrow denotes arteriotomy. (B) Access site bleeding during sheath exchange, while preparing to place REBOA by open cut-down. The white arrow depicts the access site with the wire protruding from the artery.

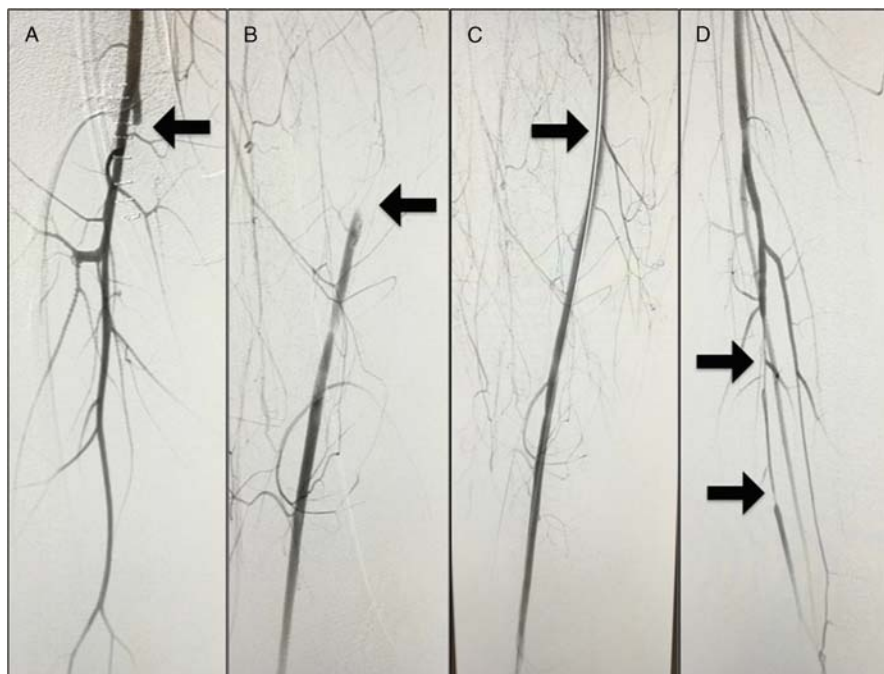


Figure 7. Angiography of the left lower extremity shortly after index procedure, following removal of ER-REBOA catheter and 7 Fr sheath. (A) Arrows denote occlusion of the SFA with (B) reconstitution of the above-the-knee popliteal artery. (C) Restored distal flow following AngioJet thromboembolectomy of the SFA. AngioJet catheter indicated by arrow. (D) Vasospasm of the posterior tibial artery prior to treatment with nitroglycerin and tPA. Black arrows denote areas of spasm.

primary repair is attempted, the surgeon should ensure that a dissection flap is not present. If isolated vasospasm or thrombosis is present, tissue plasminogen activator or papaverine administration locally may be considered. Multiple authors have observed resolution of partial thrombosis with these local maneuvers (Fig. 7).

Once the sheath is removed, the access site should have manual or ultrasound compression to prevent hematoma or pseudoaneurysm. Percutaneous closure devices have been used with some success. The access site and distal extremities should be closely monitored, and practitioners should have a low threshold for re-exploration. A thromboembolic event to any part of the leg is possible. Therefore, there is a need to image the entire leg if no distal pulses are present. The net effect is that these patients will almost always require monitoring in an intensive care unit during and immediately after REBOA. Lastly, several of the authors have observed hepatic and renal failure following prolonged Zone I REBOA inflation, and vigilance must be maintained for the onset of organ failure after REBOA.

CONCLUSIONS

Use of REBOA is increasing for the management of non-compressible hemorrhage from traumatic and nontraumatic sources. Although effective at creating temporary hemorrhage control, the procedure confers risks associated with arterial access and induces physiologic derangements. All providers should realize that the technique of REBOA is a hemorrhage control adjunct. Resuscitative endovascular balloon occlusion of the aorta creates an abnormal physiologic state in which a portion of the body undergoes profound ischemia. An area of near-universal agreement among the authors is that anytime REBOA is used,

hemorrhage control needs to be rapidly obtained, and delays in care should be avoided.

As experience with the technique increases, more evidence-based information regarding the incidence and management of complications will be elucidated in the literature. However, until such data are available, it is our hope that practitioners have access to potential complications that other users have experienced. This article assembles anecdotal complications from high-volume users in order to make them available for review and discussion. Furthermore, it attempts to build a consensus model on complications recognition, avoidance, and mitigation. It is our belief that an understanding of the pitfalls of REBOA and strategies to mitigate their occurrence is of vital importance to optimize patient outcomes.

AUTHORSHIP

A.J.D., R.M.R., V.A.R., J.J.D., and E.E.M. performed Literature Search. A.J.D., R.M.R., V.A.R., and J.J.D. designed the study. A.J.D., R.M.R., V.A.R., M.L.B., L.J.M., C.B., E.B., J.J.D., E.E.M., T.E.R., and the Study Group performed contribution of complications. A.J.D., R.M.R., V.A.R., M.L.B., L.J.M., C.B., E.B., J.J.D., E.E.M., T.E.R., and the Study Group prepared the manuscript. A.J.D., R.M.R., V.A.R., M.L.B., L.J.M., C.B., E.B., J.J.D., E.E.M., and T.E.R. critically reviewed the manuscript.

ACKNOWLEDGMENT

The authors thank all the members of the BEST study group who contributed clinical cases and critically reviewed the manuscript of this study.

DISCLOSURE

There was no funding from the Wellcome Trust or the Howard Hughes Medical Institute (HHMI) for this work. M.L.B. is on the advisory board of Prytime Medical in Boerne, Texas, and has stock with the company. The authors declare no other conflicts of interest.

REFERENCES

- Hughes CW. Use of an intra-aortic balloon catheter tamponade for controlling intra-abdominal hemorrhage in man. *Surgery*. 1954;36(1):65–68.
- Howard E, Young A. Control of aortic haemorrhage by balloon catheter. *Br Med J*. 1971;3(5767):161.
- Armour RH, Clifton MA, Marsh CH. Balloon catheter control of a ruptured abdominal aortic aneurysm in a patient with Cullen's sign. *Br J Surg*. 1978;65(5):350–351.
- Gupta BK, Khaneja SC, Flores L, Eastlick L, Longmore W, Shaftan GW. The role of intra-aortic balloon occlusion in penetrating abdominal trauma. *J Trauma*. 1989;29(6):861–865.
- Martinelli T, Thony F, Decléty P, Sengel C, Broux C, Tonetti J, Payen JF, Ferretti G. Intra-aortic balloon occlusion to salvage patients with life-threatening hemorrhagic shocks from pelvic fractures. *J Trauma*. 2010;68(4):942–948.
- Ball CG, Wyrzykowski AD, Nicholas JM, Rozycki GS, Feliciano DV. A decade's experience with balloon catheter tamponade for the emergency control of hemorrhage. *J Trauma*. 2011;70(2):330–333.
- Moore LJ, Brenner M, Kozar RA, Pasley J, Wade CE, Baraniuk MS, Scalea T, Holcomb JB. Implementation of resuscitative endovascular balloon occlusion of the aorta as an alternative to resuscitative thoracotomy for noncompressible truncal hemorrhage. *J Trauma Acute Care Surg*. 2015;79(4):523–530; discussion 530–2.
- Burkhardt GE, Rasmussen TE, Propper BW, Lopez PL, Gifford SM, Clouse WD. A national survey of evolving management patterns for vascular injury. *J Surg Educ*. 2009;66(5):239–247.
- DuBose J, Brenner ML, Cannon J, Rasmussen TE, Holcomb JB, Scalea TM. Aortic occlusion for resuscitation in trauma and acute care surgery (AORTA): a prospective observational study of the Endovascular Skills in Trauma and Resuscitative Surgery. Available at: <http://www.aast.org/library/detail.aspx?cid=e63cfff0e-54f9-4125-b3ab-6edb10dd5e9c>. Accessed July 2017.
- DuBose JJ, Scalea TM, Brenner M, Skiada D, Inaba K, Cannon J, Moore L, Holcomb J, Turay D, Arbabi CN. The AAST Prospective Aortic Occlusion for Resuscitation in Trauma and Acute Care Surgery (AORTA) registry: data on contemporary utilization and outcomes of aortic occlusion and resuscitative balloon occlusion of the aorta (REBOA). *J Trauma Acute Care Surg*. 2016;81(3):409–419.
- Matsumura Y, Matsumoto J, Kondo H, Idoguchi K, Funabiki T. Partial occlusion, conversion from thoracotomy, undelayed but shorter occlusion: resuscitative endovascular balloon occlusion of the aorta strategy in Japan [published online ahead of print March 21, 2017]. *Eur J Emerg Med*. 2017.
- Fink A, Kosecoff J, Chassin M, Brook RH. Consensus methods: characteristics and guidelines for use. *Am J Public Health*. 1984;74(9):979–983.
- Stannard A, Eliason JL, Rasmussen TE. Resuscitative endovascular balloon occlusion of the aorta (REBOA) as an adjunct for hemorrhagic shock. *J Trauma*. 2011;71(6):1869–1872.
- Brenner M, Hoehn M, Pasley J, Dubose J, Stein D, Scalea T. Basic endovascular skills for trauma course: bridging the gap between endovascular techniques and the acute care surgeon. *J Trauma Acute Care Surg*. 2014;77(2):286–291.
- Villamaria CY, Eliason JL, Napolitano LM, Stansfield RB, Spencer JR, Rasmussen TE. Endovascular Skills for Trauma and Resuscitative Surgery (ESTARS) course: curriculum development, content validation, and program assessment. *J Trauma Acute Care Surg*. 2014;76(4):929–935.
- Reva VA, Hörer T, Makhnovskiy AI, Sokhranov MV, Samokhvalov IM, DuBose JJ. Field and en route REBOA: a feasible military reality? *J Trauma Acute Care Surg*. 2017;83(1):S170–S176.
- Romagnoli A, Teeter W, Pasley J, Hu P, Hagegeorge G, Stein D, Scalea T, Megan B, eds. Time to aortic occlusion: it's all about access. Presented at the Annual Meeting of the American Association for the Surgery of Trauma (AAST); September 14–17, 2016; Hilton Waikoloa Village, HI.
- Moore HB, Moore EE, Liras IN, Wade C, Huebner BR, Burlew CC, Pieracci FM, Sautia A, Cotton BA. Targeting resuscitation to normalization of coagulation status—hyper and hypo coagulopathy after severe injury are both associated with increased mortality. *Am J Surg*. 2017. In press. Epub ahead of print.
- Schnyder G, Sawhney N, Whisenant B, Tsimikas S, Turi ZG. Common femoral artery anatomy is influenced by demographics and comorbidity: implications for cardiac and peripheral invasive studies. *Catheter Cardiovasc Interv*. 2001;53(3):289–295.
- Hilty WM, Hudson PA, Levitt MA, Hall JB. Real-time ultrasound-guided femoral vein catheterization during cardiopulmonary resuscitation. *Ann Emerg Med*. 1997;29(3):331–336.
- Hörer TM. *Top Stent*. 1st ed. Örebro, Sweden: Örebro University Hospital; 2017.
- Taylor JR 3rd, Harvin JA, Martin C, Holcomb JB, Moore LJ. Vascular complications from resuscitative endovascular balloon occlusion of the aorta: life over limb? *J Trauma Acute Care Surg*. 2017;83(1 Suppl 1):S120–S123.
- DuBose JJ. How I do it: partial resuscitative endovascular balloon occlusion of the aorta (P-REBOA). *J Trauma Acute Care Surg*. 2017;83(1):197–199.
- Arthurs Z, Starnes B, See C, Andersen C. Clamp before you cut: proximal control of ruptured abdominal aortic aneurysms using endovascular balloon occlusion—case reports. *Vasc Endovascular Surg*. 2006;40(2):149–155.
- Hörer TM, Skoog P, Pirouzram A, Nilsson KF, Larzon T. A small case series of aortic balloon occlusion in trauma: lessons learned from its use in ruptured abdominal aortic aneurysms and a brief review. *Eur J Trauma Emerg Surg*. 2016;42(5):585–592.
- Madurska MJ, Jansen JO, Reva VA, Mirghani M, Morrison JJ. The compatibility of computed tomography scanning and partial REBOA: a large animal pilot study. *J Trauma Acute Care Surg*. 2017;83(3):557–561.
- Saito N, Matsumoto H, Yagi T, Hara Y, Hayashida K, Motomura T, Mashiko K, Iida H, Yokota H, Wagatsuma Y. Evaluation of the safety and feasibility of resuscitative endovascular balloon occlusion of the aorta. *J Trauma Acute Care Surg*. 2015;78(5):897–903.
- Brenner ML, Moore LJ, DuBose JJ, Tyson GH, McNutt MK, Albarado RP, Holcomb JB, Scalea TM, Rasmussen TE. A clinical series of resuscitative endovascular balloon occlusion of the aorta for hemorrhage control and resuscitation. *J Trauma Acute Care Surg*. 2013;75(3):506–511.
- Gelman S. The pathophysiology of aortic cross-clamping and unclamping. *Anesthesiology*. 1995;82(4):1026–1060.
- Gelman S, Khazaeli M, Orr R, Henderson T, Reves J. Blood volume redistribution during cross-clamping of the descending aorta. *Anesth Analg*. 1994;78(2):219–224.
- Fox CJ. A novel low-profile ER-REBOA catheter is not fluoroscopy-free. *J Trauma Acute Care Surg*. 2016;80(6):1053.
- Stensath KH, Sovik E, Haig IN, Skomedal E, Jorgensen A. Fluoroscopy-free resuscitative endovascular balloon occlusion of the aorta (REBOA) for controlling life threatening postpartum hemorrhage. *PLoS One*. 2017;12(3):e0174520.
- Linnebur M, Inaba K, Haltmeier T, Rasmussen TE, Smith J, Mendelsberg R, Grabo D, Demetriades D. Emergent non-image-guided resuscitative endovascular balloon occlusion of the aorta (REBOA) catheter placement: a cadaver-based study. *J Trauma Acute Care Surg*. 2016;81(3):453–457.
- Pezy P, Flaris AN, Prat NJ, Cotton F, Lundberg PW, Caillot JL, David JS, Voiglio EJ. Fixed-distance model for balloon placement during fluoroscopy-free resuscitative endovascular balloon occlusion of the aorta in a civilian population. *JAMA Surg*. 2017;152(4):351–358.
- Scott DJ, Eliason JL, Villamaria C, Morrison JJ, Houston R 4th, Spencer JR, Rasmussen TE. A novel fluoroscopy-free, resuscitative endovascular aortic balloon occlusion system in a model of hemorrhagic shock. *J Trauma Acute Care Surg*. 2013;75(1):122–128.
- Guliani S, Amendola M, Strife B, Morano G, Elbich J, Albuquerque F, Komorowski D, Sydnor M, Malhotra A, Levy M. Central aortic wire confirmation for emergent endovascular procedures: as fast as surgeon-performed ultrasound. *J Trauma Acute Care Surg*. 2015;79(4):549–554.
- Ogura T, Lefor AK, Nakamura M, Fujizuka K, Shiroto K, Nakano M. Ultrasound-guided resuscitative endovascular balloon occlusion of the aorta in the resuscitation area. *J Emerg Med*. 2017;52(5):715–722.
- Hörer TM, Cajander P, Jans A, Nilsson KF. A case of partial aortic balloon occlusion in an unstable multi-trauma patient. *Trauma*. 2016;1460408615624727.
- Davidson AJ, Russo RM, DuBose JJ, Roberts J, Jurkovich GJ, Galante JM. Potential benefit of early operative utilization of low profile, partial resuscitative endovascular balloon occlusion of the aorta (P-REBOA) in major traumatic hemorrhage. *J Trauma Acute Care Surg Open*. 2016;1(1):e000028.
- Johnson MA, Neff LP, Williams TK, DuBose JJ. EVAC Study Group. Partial resuscitative balloon occlusion of the aorta (P-REBOA): clinical technique and rationale. *J Trauma Acute Care Surg*. 2016;81(5):S133–S137.

41. Matsuda H, Tanaka Y, Hino Y, Matsukawa R, Ozaki N, Okada K, Tsukube T, Tsuji Y, Okita Y. Transbrachial arterial insertion of aortic occlusion balloon catheter in patients with shock from ruptured abdominal aortic aneurysm. *J Vasc Surg*. 2003;38(6):1293–1296.
42. Søvik E, Stokkeland P, Storm B, Åsheim P, Bolås O. The use of aortic occlusion balloon catheter without fluoroscopy for life-threatening post-partum haemorrhage. *Acta Anaesthesiol Scand*. 2012;56(3):388–393.
43. Inoue J, Shiraiishi A, Yoshiyuki A, Haruta K, Matsui H, Otomo Y. Resuscitative endovascular balloon occlusion of the aorta might be dangerous in patients with severe torso trauma: a propensity score analysis. *J Trauma Acute Care Surg*. 2016;80(4):559–566.
44. Uchino H, Tamura N, Echigoya R, Ikegami T, Fukuoka T. “REBOA”—is it really safe? A case with massive intracranial hemorrhage possibly due to endovascular balloon occlusion of the aorta (REBOA). *Am J Case Rep*. 2016;17:810–813.
45. Biffl WL, Fox CJ, Moore EE. The role of REBOA in the control of exsanguinating torso hemorrhage. *J Trauma Acute Care Surg*. 2015;78(5):1054–1058.
46. Avaro JP, Mardelle V, Roch A, Gil C, de Biasi C, Oliver M, Fusai T, Thomas P. Forty-minute endovascular aortic occlusion increases survival in an experimental model of uncontrolled hemorrhagic shock caused by abdominal trauma. *J Trauma*. 2011;71(3):720–725.
47. Irahara T, Sato N, Moroe Y, Fukuda R, Iwai Y, Unemoto K. Retrospective study of the effectiveness of intra-aortic balloon occlusion (IABO) for traumatic haemorrhagic shock. *World J Emerg Surg*. 2015;10(1):1.
48. Markov NP, Percival TJ, Morrison JJ, Ross JD, Scott DJ, Spencer JR, Rasmussen TE. Physiologic tolerance of descending thoracic aortic balloon occlusion in a swine model of hemorrhagic shock. *Surgery*. 2013;153(6):848–856.
49. Russo RM, Neff LP, Johnson MA, Williams TK. Emerging endovascular therapies for non-compressible torso hemorrhage. *Shock*. 2016;46(3 Suppl 1):12–19.
50. Hörer TM, Skoog P, Nilsson KF, Oikonomakis I, Larzon T, Norgren L, Jansson K. Intraperitoneal metabolic consequences of supraceliac aortic balloon occlusion in an experimental animal study using microdialysis. *Ann Vasc Surg*. 2014;28(5):1286–1295.
51. Reva VA, Matsumura Y, Hörer T, Sveklöv DA, Denisov AV, Telickiy SY, Seleznev AB, Bozhedomova ER, Matsumoto J, Samokhvalov IM. Resuscitative endovascular balloon occlusion of the aorta: what is the optimum occlusion time in an ovine model of hemorrhagic shock? *Eur J Trauma Emerg Surg*. 2016:1–8.
52. Pascal O, Wajzman Z, Jennings E. Intermittent occlusion of the abdominal aorta: a conceptual approach in treating below-diaphragm tumors (a preliminary report). *J Surg Oncol*. 1978;10(3):225–237.
53. Manning JE, Ross JD, McCurdy SL, True NA. Aortic hemostasis and resuscitation: preliminary experiments using selective aortic arch perfusion with oxygenated blood and intra-aortic calcium coadministration in a model of hemorrhage-induced traumatic cardiac arrest. *Acad Emerg Med*. 2016;23(2):208–212.
54. Williams TK, Neff LP, Johnson MA, Russo RM, Ferencz SA, Davidson AJ, Rasmussen TE. Extending resuscitative endovascular balloon occlusion of the aorta: endovascular variable aortic control in a lethal model of hemorrhagic shock. *J Trauma Acute Care Surg*. 2016;81(2):294–301.
55. Johnson MA, Davidson AJ, Russo RM, Ferencz S-AE, Gotlib O, Rasmussen TE, Neff LP, Williams TK. Small changes, big effects: the hemodynamics of partial and complete aortic occlusion to inform next generation resuscitation techniques and technologies. *J Trauma Acute Care Surg*. 2017;82(6):1106–1111.
56. Johnson MA, Williams TK, Ferencz SE, Davidson AJ, Russo RM, O'Brien WT Sr, Galante JM, Grayson JK, Neff LP. The effect of REBOA, partial aortic occlusion and aggressive blood transfusion on traumatic brain injury in a swine polytrauma model [published online ahead of print April 27, 2017]. *J Trauma Acute Care Surg*. 2017.
57. Russo RM, Neff LP, Lamb CM, Cannon JW, Galante JM, Clement NF, Grayson JK, Williams TK. Partial resuscitative endovascular balloon occlusion of the aorta in swine model of hemorrhagic shock. *J Am Coll Surg*. 2016;223(2):359–368.
58. Russo RM, Williams TK, Grayson JK, Lamb CM, Cannon JW, Clement NF, Galante JM, Neff LP. Extending the golden hour: partial resuscitative endovascular balloon occlusion of the aorta in a highly lethal swine liver injury model. *J Trauma Acute Care Surg*. 2016;80(3):372–378; discussion 8–80.
59. Williams TK, Neff LP, Johnson MA, Russo RM, Ferencz S-A, Davidson AJ, Clement NF, Grayson JK, Rasmussen TE. Automated variable aortic control versus complete aortic occlusion in a swine model of hemorrhage. *J Trauma Acute Care Surg*. 2017;82(4):694–703.
60. Malina M, Veith F, Ivancev K, Sonesson B. Balloon occlusion of the aorta during endovascular repair of ruptured abdominal aortic aneurysm. *J Endovasc Ther*. 2005;12(5):556–559.
61. Davidson AJ, Russo RM, Ferencz S-AE, Cannon JW, Rasmussen TE, Neff LP, Johnson MA, Williams TK. Incremental balloon deflation following complete resuscitative endovascular balloon occlusion of the aorta results in steep inflection of flow and rapid reperfusion in a large animal model of hemorrhagic shock. *J Trauma Acute Care Surg*. 2017;83(1):139–143.
62. Moore HB, Moore EE, Gonzalez E, Huebner BJ, Sheppard F, Banerjee A, Sauaia A, Silliman CC. Reperfusion shutdown: delayed onset of fibrinolysis resistance after resuscitation from hemorrhagic shock is associated with increased circulating levels of plasminogen activator inhibitor-1 and postinjury complications. *Blood*. 2016;128(22):22.
63. Norii T, Crandall C, Terasaka Y. Survival of severe blunt trauma patients treated with resuscitative endovascular balloon occlusion of the aorta compared with propensity score-adjusted untreated patients. *J Trauma Acute Care Surg*. 2015;78(4):721–728.
64. Teeter WA, Matsumoto J, Idoguchi K, Kon Y, Orita T, Funabiki T, Brenner ML, Matsumura Y. Smaller introducer sheaths for REBOA may be associated with fewer complications. *J Trauma Acute Care Surg*. 2016;81(6):1039–1045.
65. Koenigsberg RA, Wysoki M, Weiss J, Faro SH, Tsai FY. Risk of clot formation in femoral arterial sheaths maintained overnight for neuroangiographic procedures. *AJNR Am J Neuroradiol*. 1999;20(2):297–299.
66. Benson LM, Wunderly D, Perry B, Kabboord J, Wenk T, Birdsall B. Determining best practice: comparison of three methods of femoral sheath removal after cardiac interventional procedures. *Heart Lung*. 2005;34(2):115–121.
67. Norii T, Miyata S, Terasaka Y, Guliani S, Lu SW, Crandall C. Resuscitative endovascular balloon occlusion of the aorta in trauma patients in youth. *J Trauma Acute Care Surg*. 2017;82(5):915–920.